

# 壁細胞機能不全に伴う 多発胃NETの1例

Clinical Journal of Gastroenterology  
<https://doi.org/10.1007/s12328-022-01704-7>

CASE REPORT



**A rare case of an enterochromaffin-like neuroendocrine tumor associated with parietal cell dysfunction treated using endoscopic submucosal dissection**

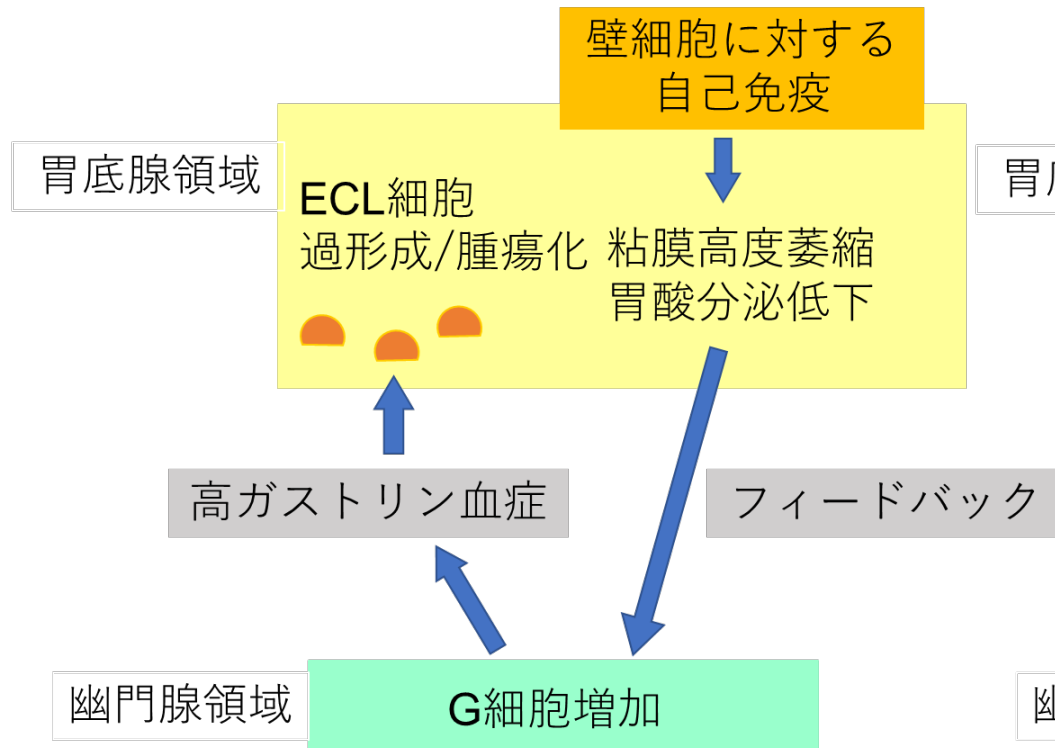
Sho Shiroma<sup>1</sup> · Kayoko Higuchi<sup>2</sup> · Hiroyoshi Ota<sup>3</sup> · Junji Umeno<sup>4</sup> · Mitsuaki Ishioka<sup>5</sup> · Toshiaki Hirasawa<sup>5</sup> · Hiroko Kuba<sup>1</sup> · Takeshi Ono<sup>6</sup> · Ryoji Uchima<sup>2</sup> · Ryoji Nagamura<sup>1</sup>

沖縄協同病院 消化器内科  
一銀内科胃腸科クリニック

城間 翔

# 壁細胞機能不全に伴う 胃NETの発生機序

a: 自己免疫性胃炎



b: 壁細胞機能不全症

